Marieb's Human Anatomy and Physiology

Marieb ◆ Hoehn

Chapter 6
Bones and Skeletal Tissue
Lecture 13

1

Lecture Overview

- Introduction to the skeletal system
- Function and classification of bones
- Structure of bones
- Bone development and growth
- Bone homeostasis
- Factors affecting bone growth, development and repair
- Functions of bone

2

Overview of the Skeletal System

- The human skeleton contains a total of 206 bones
  - 80 Axial
  - 126 Appendicular
- Bone is also called osseous tissue and is a hard (supporting) form of connective tissue composed of two (2) types of bone
  - Compact bone (osteons are the main units)
  - Spongy (cancellous) bone

3

Skeletal System Functions

- **Support and Protection**
  - **gives shape to head, etc.**
  - **supports body's weight**
  - **protects thoracic organs and brain**
- **Body Movement**
  - **interacts with muscles**
  - **bones act as rigid bar of a lever**
- **Blood Cell Formation**
  - **hematopoiesis**
  - **red marrow**
- **Inorganic Salt Storage**
  - **calcium**
  - **phosphate**
  - **magnesium**
  - **sodium**
  - **potassium**
  - **electrolyte and acid/base balance**

4

Components of Bone

Recall that Bone is a supporting connective tissue with cells and a matrix

- Cells (osteo-)
- Matrix
  - Organic Component (Osteoid) – approx. 35% (wt.)
    - Fibers = collagen
    - Ground Substance = proteoglycans, glycoproteins
  - Inorganic Component – approx. 65% (wt.)
    - Hydroxyapatites = Ca^{2+} PO_4^{3-} salts ($Ca_{10}(PO_4)_6(OH)_2$)

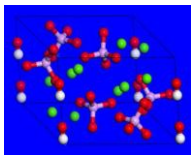

7

Cells of Bone Tissue

- **Osteoprogenitor (osteogenic) – Mesenchymal precursors of osteoblasts**
- **Osteoblasts – mesenchymal-derived; secrete matrix of bone (osteogenesis, i.e., creation of new bone)**
- **Osteo*cytes* - osteoblasts trapped in lacunae (mature cells that maintain bone)**
- **Osteoclasts – monocyte-derived; break down ('eat') bone (this is called osteolysis)**

8

Structure of a Long Bone

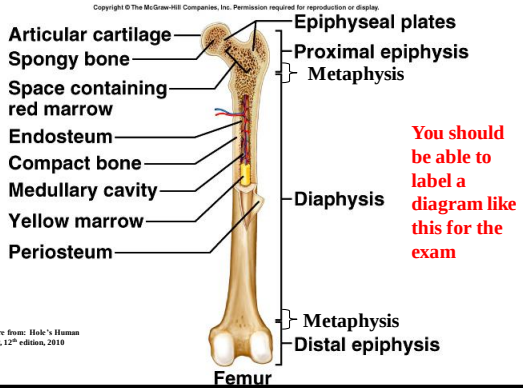

You should be able to label a diagram like this for the exam

Figure from: Hole's Human A&P, 12th edition, 2010

Compact and Spongy Bone

Each bone in the skeleton contains two forms of osseous tissue

- Compact bone (cortical) – solid (with osteons as structural units); found on outer parts of bone
- Spongy (cancellous, trabecular) bone – network of struts and plates (trabeculae); found within the inner parts of bone

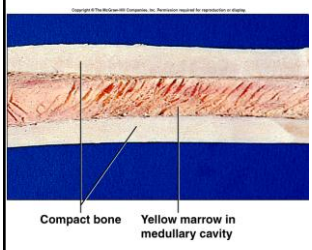

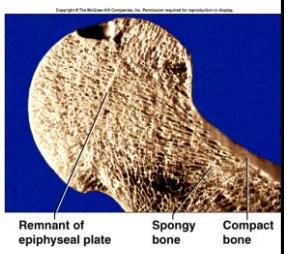

Figure from: Hole's Human A&P, 12th edition, 2010

Compact Bone

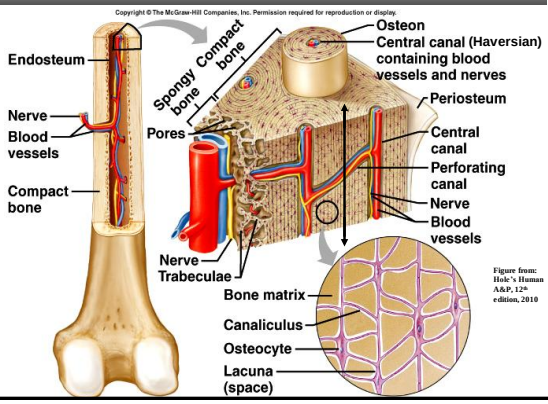

Figure from: Hole's Human A&P, 12th edition, 2010

Periosteum and Endosteum

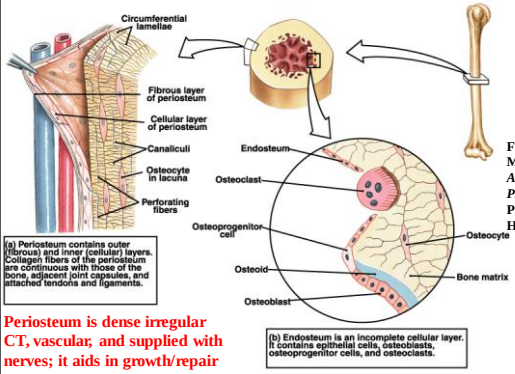

Figure from: Martini, *Anatomy & Physiology*, Prentice-Hall, 2001

Periosteum is dense irregular CT, vascular, and supplied with nerves; it aids in growth/repair

Spongy (Cancellous) Bone

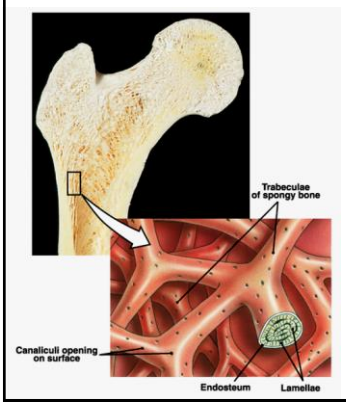

- **Spongy bone is NOT arranged in osteons**
- **Matrix forms struts and plates called trabeculae**
- **Located where bones are not heavily stressed or stress arrives in different directions**
- **Lightweight and strong**
- **Supports and protects cells of the red marrow**

Figure from: Martini, *Anatomy & Physiology*, Prentice-Hall, 2001

Trabeculae of Spongy Bone

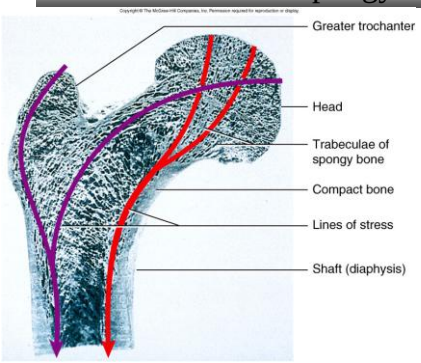

Notice how the trabeculae of spongy bone can be seen oriented along lines of mechanical stress applied by the weight of the body

Figure from: Saladin, *Anatomy & Physiology*, McGraw Hill, 2007

Bone Growth and Development

Ossification (osteogenesis) – replacement of other tissues with bone (different than calcification)

Bone is formed by <u>replacement of other types of connective tissue</u> in one of two ways:

Intramembranous Ossification
- **bones originate within sheetlike layers of fibrous or mesenchymal connective tissues**
- **broad, flat bones**
- **skull bones, clavicle (collarbone), mandible**
- **forms the intramembranous bones**

Endochondral Ossification
- **bones begin as hyaline cartilage**
- **most bones of the skeleton**
- **forms the endochondral bones**

15

Bone Growth and Development

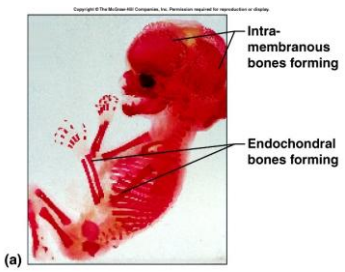

14-week fetus

Figure from: Hole's Human A&P, 12th edition, 2010

16

Intramembranous Ossification

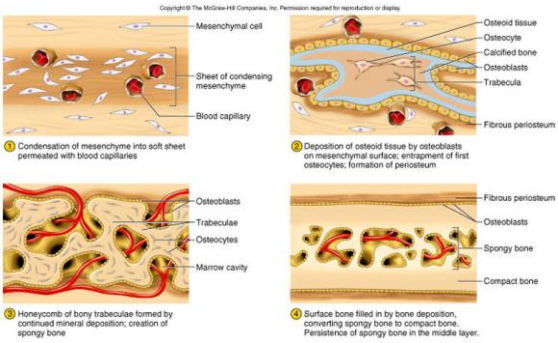

Figure from: Saladin, *Anatomy & Physiology*, McGraw Hill, 2007

17

Endochondral Ossification

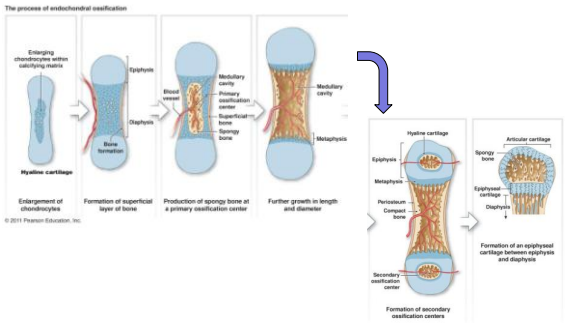

Intramembranous vs. Endochondral Ossification

TABLE 7.1 Major Steps in Bone Development

Intramembranous Ossification	Endochondral Ossification
1. Sheets of primitive connective tissue appear at sites of future bones.	1. Masses of hyaline cartilage form models of future bones.
2. Primitive connective tissue cells collect around blood vessels in these layers.	2. Cartilage tissue breaks down. Periosteum develops.
3. Connective tissue cells differentiate into osteoblasts, which deposit spongy bone.	3. Blood vessels and differentiating osteoblasts from the periosteum invade the disintegrating tissue.
4. Osteoblasts become osteocytes when bony matrix completely surrounds them.	4. Osteoblasts form spongy bone in the space occupied by cartilage.
5. Connective tissue on the surface of each developing structure forms a periosteum.	5. Osteoblasts become osteocytes when bony matrix completely surrounds them.
6. Osteoblasts on the inside of the periosteum deposit compact bone over the spongy bone.	6. Osteoblasts beneath the periosteum deposit compact bone around spongy bone.

Table from: Hole's Human A&P, 12th edition, 2010

For Intramembranous and Endochonral Ossification you should know:
1) The starting material for each process
2) Which bones form by each process

Epiphyseal Plates

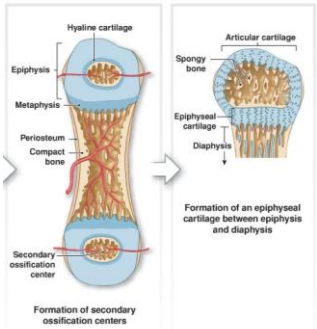

Epiphyseal cartilage = epiphyseal plate; allows long bones to grow in length

Growth at the Epiphyseal Plate

First layer of cells
- proximal end of epiphysis
- resting cells
- anchors epiphyseal plate to epiphysis

Second layer of cells
- many rows of young cells
- undergoing mitosis
- active growth occurs here

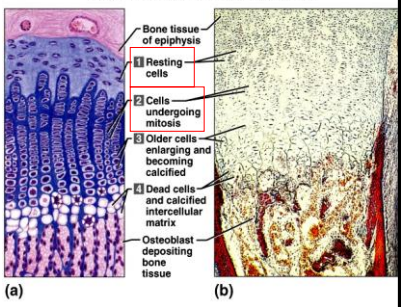

Figure from: Hole's Human A&P, 12th edition, 2010

Growth at the Epiphyseal Plate

Third layer of cells
- older cells
- left behind when new cells appear
- cells enlarging and becoming calcified

Fourth layer of cells
- thin
- dead cells
- calcified intercellular substance

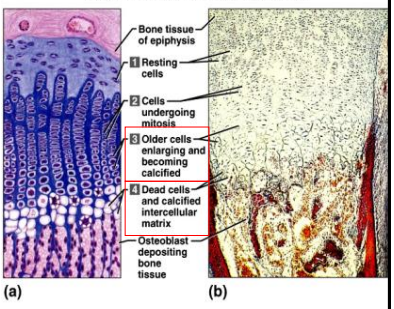

Figure from: Hole's Human A&P, 12th edition, 2010

Growth at the Epiphyseal Plate

Figure from: Hole's Human A&P, 12th edition, 2010

Epiphyseal cartilages

Epiphyseal lines

Fractures involving the epiphyseal plate are of great concern.

If not repaired correctly, bone may prematurely stop elongating, or growth may be unequal with respect to the unaffected limb.

Homeostasis of Bone Tissue

Bone remodeling is a process that continues throughout life, and is accomplished by two processes:

1) Bone Resorption (destruction of bone)– action of osteoclasts and parathyroid hormone (PTH)
2) Bone Deposition (creation of bone) – action of osteoblasts and calcitonin

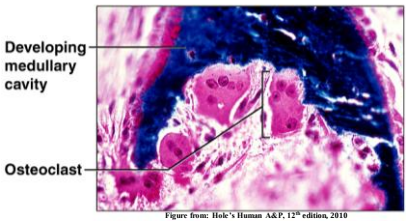

Figure from: Hole's Human A&P, 12th edition, 2010

Factors Affecting Bone Remodeling, Growth, and Repair

- **Mineral salts, especially Calcium and Phosphorus**
- **Vitamins A, C, and D**
  - Deficiency of Vitamin A – retards bone development
  - Deficiency of Vitamin C – results in fragile (brittle) bones
  - Deficiency of Vitamin D – rickets, osteomalacia
- **Growth factors and Hormones**
  - Sex Hormones – promote bone formation; stimulate ossification (closure) of epiphyseal plates
  - Insulin-like growth factors (IGFs) – stim. by hGH
  - Insufficient Growth Hormone – pituitary dwarfism
  - Excessive Growth Hormone – gigantism, acromegaly
  - Insufficient Thyroid Hormone – delays bone growth
- **Physical Stress (exercise) – stimulates bone growth**

Bone is an Inorganic Salt Reservoir

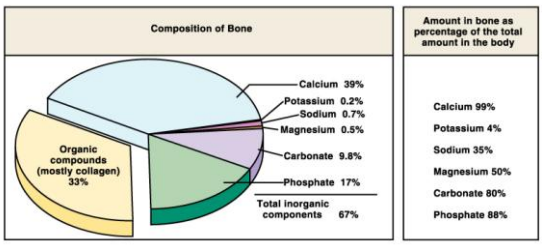

Hydroxyapatite = Ca^{2+} salts $[Ca_{10}(PO_4)_6(OH)_2]$

Figures from: Martini, *Anatomy & Physiology*, Prentice-Hall, 2001

Calcium Homeostasis

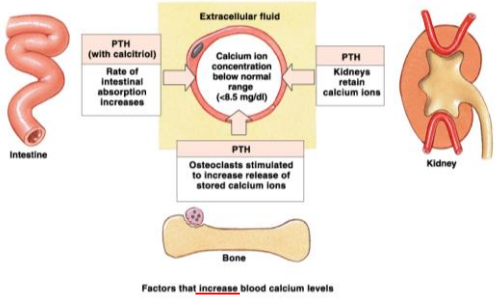

Parathyroid hormone (PTH) ↑ blood calcium

Figure from: Martini, *Anatomy & Physiology*, Prentice-Hall, 2001

28

Calcium Homeostasis

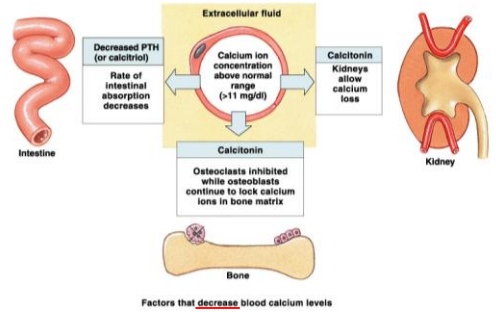

Calcitonin ↓ blood calcium

Figure from: Martini, *Anatomy & Physiology*, Prentice-Hall, 2001

29

Blood Cell Formation

- Hematopoiesis is the process of blood cell formation (also called 'hemopoiesis')
- At different points in development, hematopoiesis takes place in the:
  - Yolk sac (embryo)
  - Liver and spleen (fetus)
  - Red bone marrow (fetus, newborn, and adult)

30

Blood Cell Formation Takes Place in the Red Bone Marrow

- Red marrow functions in development of
  - Myeloid cells - red blood cells, platelets, eosinophils, basophils, neutrophils, and monocytes
  - Lymphocytic cells – T lymphocytes and B lymphocytes
- Adult red marrow is primarily found in the spongy bone of the skull, ribs, sternum, clavicles, vertebrae, pelvis, and epiphyses of long bones

31

Bone Mass in Men vs. Women

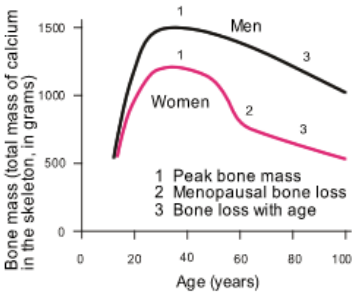

Figure from: www.arc.org.uk/.../6028/images/6028_3.gif

32

Osteoporosis

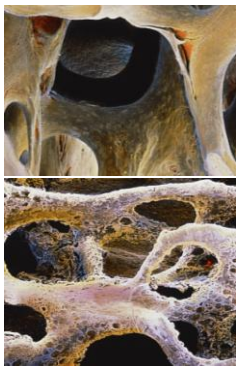

Figure from: http://www.usbjd.org/projects/images/The%2520Progression%2520of%2520Osteoporosis.jpg

Figures from: Martini, *Anatomy & Physiology*, Prentice-Hall, 2001

33

Bone Fractures

Figure from: Hole's Human A&P, 12th edition, 2010

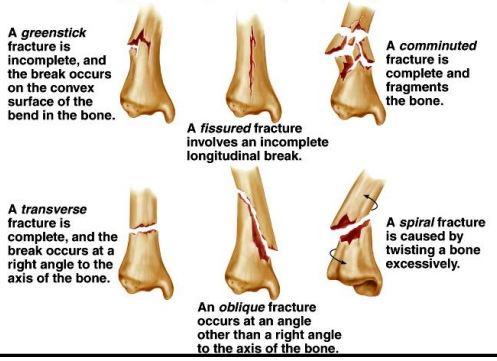

Healing of Fractures

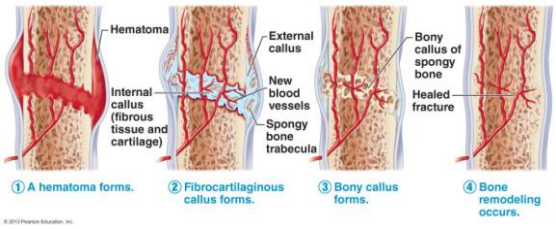

Figure From: Marieb & Hoehn, *Human Anatomy & Physiology*, 9th ed., Pearson